



PATIENT

Olive Lehman

SPECIES

Canine

BREED

Sheltie

SEX

Female Spayed

AGE

1.20.14

WEIGHT

19.7lbs

INTERPRETED BY

Maggie Machen Lamy,
DVM, DACVIM
(Cardiology)

HOSPITAL NAME

Hickory Veterinary
Hospital

REFERRING VET

Dr. Lyle

INVOICE

24906

DATE

6.21.22

PRESENTING CLINICAL SIGNS

History: Recheck echo. Patient doing well clinically.

-Pertinent abnormal PE/Chem/CBC/UA Results: 5/7/22- ALKP 586, ALT 133.

-Current medications: Furosemide 10mg SID, Pimobendan 2.5mg BID, Spironolactone 12.5mg BID.

-Sedation used: Not required to complete full diagnostic ultrasound.

-Pertinent previous ultrasound results (5/18/21 MML): severe LA/LVE, mod MR, mild RHE; LA 3.1 LV 4.1/3.5 FS 15% TR 2.3m/s

-STAT: Declined.

-Imaging performed by: Stephanie Pearce RDCS, RVT.

ECHOCARDIOGRAM FINDINGS

2D, m-mode, color flow and doppler imaging is available. Significant left ventricular dilation with decreased systolic function and increased sphericity. Decreased LV wall thickness. Severe left atrial enlargement. The mitral valve appears mildly thickened, with no obvious prolapse into the left atrial lumen. Mild to moderate eccentric mitral regurgitation. Elevated velocity. Tricuspid valve appears normal in form and function. Mild right atrial and ventricular dilation. No significant tricuspid regurgitation. The aortic valve is normal in morphology and mobility. Normal LVOT and RVOT velocities. No aortic or pulmonic insufficiency. No pericardial or pleural effusion noted. No obvious cardiac tumors.

CARDIAC CHART

CANINE CARDIAC PARAMETERS	MR VMAX (m/s)	TR VMAX (m/s)	LA/AO (Boon method)	LA/AO (Heart Base; Swe)	FS (%)	EF (%)	EPSS (cm)
NORMAL PARAMETER	4.5-5.5	<2.7	1.3	<1.6	28-40	40-100	<0.6
PATIENT	6.4		NM	2.4	19	36	NM
CANINE CARDIAC PARAMETERS	HR (BPM)	AV VMAX (m/s)	PV MAX (m/s)	BODY WEIGHT (kg)	LA 2D short axis Base view (cm)	LVIDd Avg; 2D and m-mode short axis (cm)	LVIDs Avg; 2D and m-mode short axis (cm)
NORMAL PARAMETER	50-100	0.7-1.7	0.7-1.6	BELOW	BELOW	BELOW	BELOW
PATIENT	84	1.8	1.0	8.9	2.9	3.7	3.1
*Normal chamber parameters expressed as a mean value (SD)				3	1.27 (5.3)	2.46 (2.46)	1.36 (5.5)
BODY WEIGHT DEPENDENT PARAMETERS				5	1.40 (4.5)	2.74 (5.2)	1.60 (4.7)
<i>*Note: All measurements based upon multi-modal images and methods. An average value is reported.</i>				10	1.50 (3.8)	3.27 (3.5)	2.06 (3.1)
				15	1.83 (2.0)	3.71 (2.4)	2.43 (2.1)
				20	2.02 (1.9)	4.14 (2.2)	2.80 (2.0)
				25	2.18 (2.4)	4.48 (2.9)	3.10 (2.5)
				30	2.33 (3.3)	4.83 (3.9)	3.39 (3.4)
				35	2.48 (4.3)	5.17 (5.0)	3.69 (4.5)
				40	2.62 (5.2)	5.48 (6.1)	3.96 (5.4)
				50	2.88 (7.1)	6.07 (8.3)	4.46 (7.4)

Adapted from June Boon, Veterinary Echocardiography, 1998
Rishniw M and Hollis NE, J Vet Intern Med 2000; 14:429-435
Hansson et al, Vet Rad and Ultrasound 2002
Bonagura et al. Echocardiography: principles of interpretation, Vet Clin North Am 15:1177, 1995

INTERPRETATION OF THE FINDINGS & FURTHER RECOMMENDATIONS

DCM persists with evidence of slight improvement. The left heart dimensions and function are mildly improved, likely due to medical support. No obvious additional issues are identified. Regardless, the patient will always be at high risk for decompensating into congestive failure, development of arrhythmias/syncope and/or sudden death going forward.

Given these findings, continue cardiac support lifelong. Recommend BID Lasix dosing, due to post-diuretic fluid retention. A screening ECG and BP are recommended every 6 months.

Elective anesthesia is not advised due to high risk for complications.

Omega fatty acid supplementation and mild salt restriction may be of some long-term benefit. Monitor for development of a cough, worsening labored breathing, abdominal distention, exercise intolerance or collapse episodes in the future. Monitoring of sleeping breathing rates at home is recommended to assess response to medications and recurrence of CHF in the future.

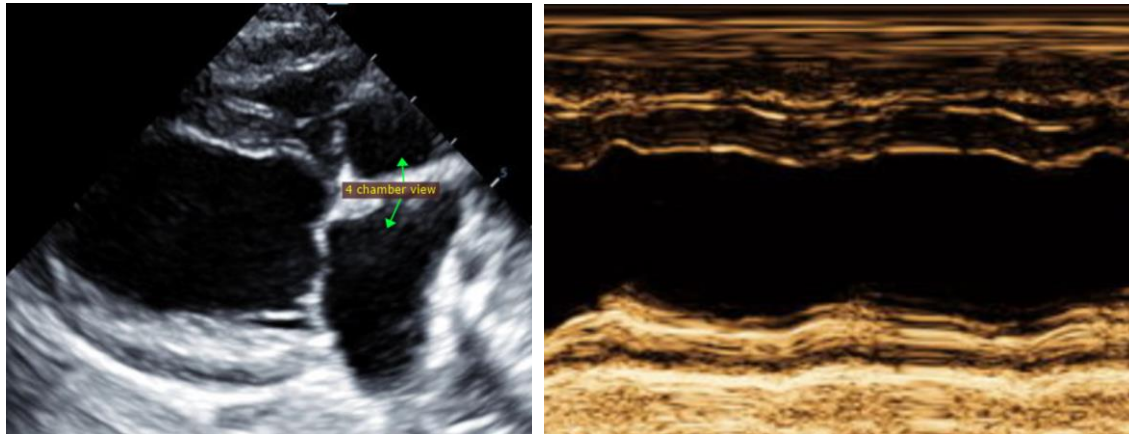
PLAN:

Continue Pimobendan and Spironolactone as prescribed. Increase Lasix to 10mg BID. Institute taurine 1000mg PO q12h.

Monitor a renal panel and blood pressure every 3-4 months lifelong.

A recheck echocardiogram is recommended in 6 months to screen for progression, sooner if clinical issues arise in the interim.

IMAGES



The information and recommendations provided are based on the images presented by the referring veterinarian. No evaluation can be communicated regarding pathology that was not visible in the image/video clips provided.

Thank you for this referral. This report was generated using transcription software, and minor dictation errors may be present. If the clinical or image interpretation does not parallel your findings or if I can be of any further assistance please contact me.

Maggie Machen Lamy, DVM
Diplomate of the American College of Veterinary Internal Medicine (Cardiology)
info@sonopath.com